



Gynecology

Gestational trophoblastic disease

University of Fallujah
College of medicine



Lecture : 4

Stage : 5th

Lecturer : dr. Huda AL-janabi

Department : Obstetrics &gynecology

Date : 24\11\2025

Learning objective

1. Differentiate between complete and partial molar pregnancies based on their **pathology and genetics** (karyotype).

2. Identify the classic **clinical signs and ultrasound findings** leading to a molar pregnancy diagnosis.

3. Outline the management plan, emphasizing **suction evacuation** and mandatory **beta-HCG surveillance**.

4. Recognize the potential for malignant transformation into **Gestational Trophoblastic Neoplasia (GTN)** and the role of beta-HCG monitoring in its early detection.

- ▶ Gestational trophoblastic diseases (GTD) covers a spectrum of diseases caused by overgrowth of the placenta. This includes hydatidiform mole, choriocarcinoma, invasive mole, and placental site trophoblastic tumor .
- ▶ Incidence:0.6–2.3:1000 pregnancies .
- ▶ 50% of cases follow hydatidiform mole, 25% a normal pregnancy, and 25% a miscarriage or ectopic pregnancy .

▶ **Hydatidiform mole :**

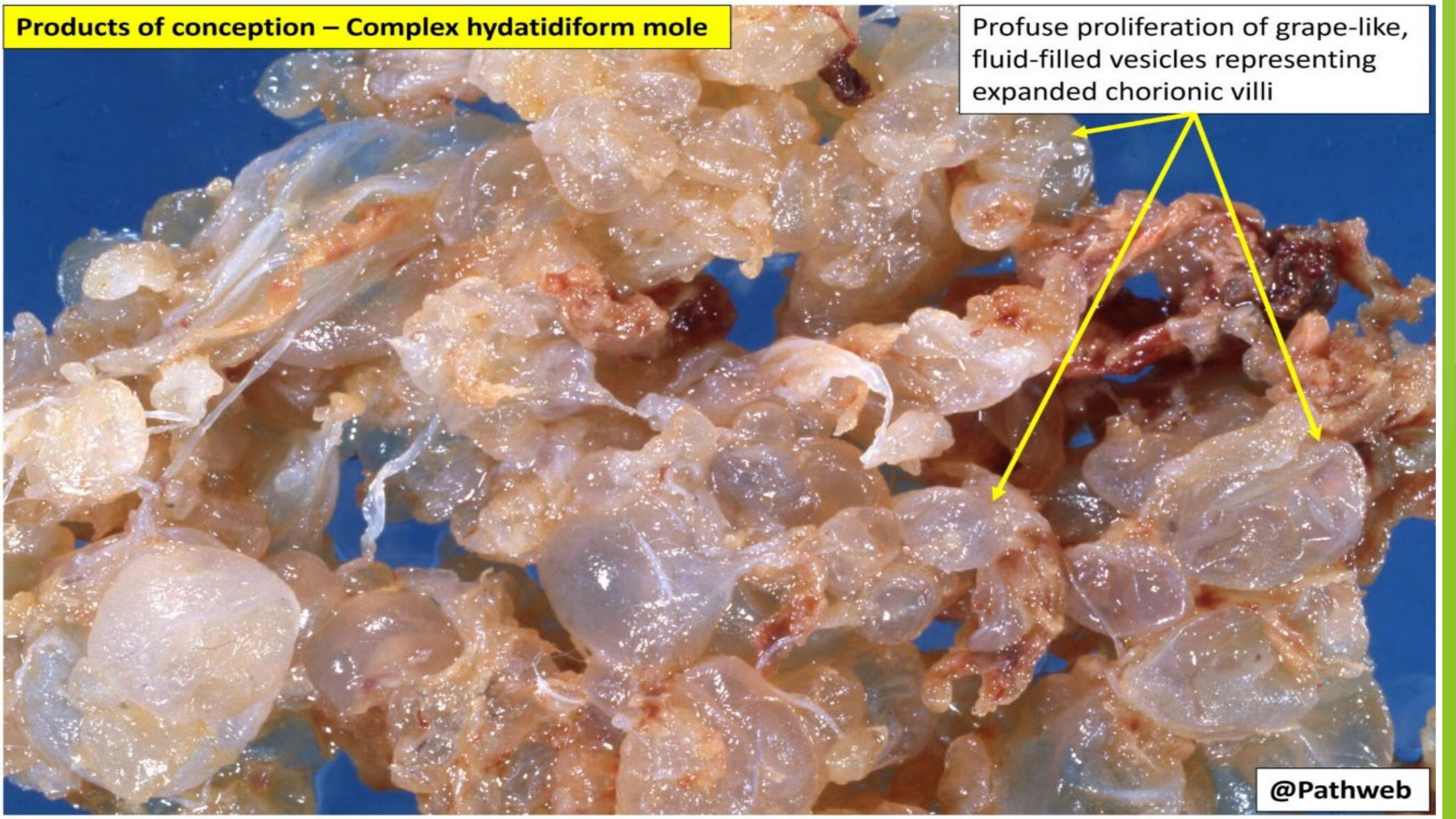
- ▶ A hydatidiform mole (or molar pregnancy) is a rare, premalignant form of Gestational Trophoblastic Disease (GTD) resulting from abnormal fertilization. Can be subdivided into complete and partial mole based on genetic and histological features .

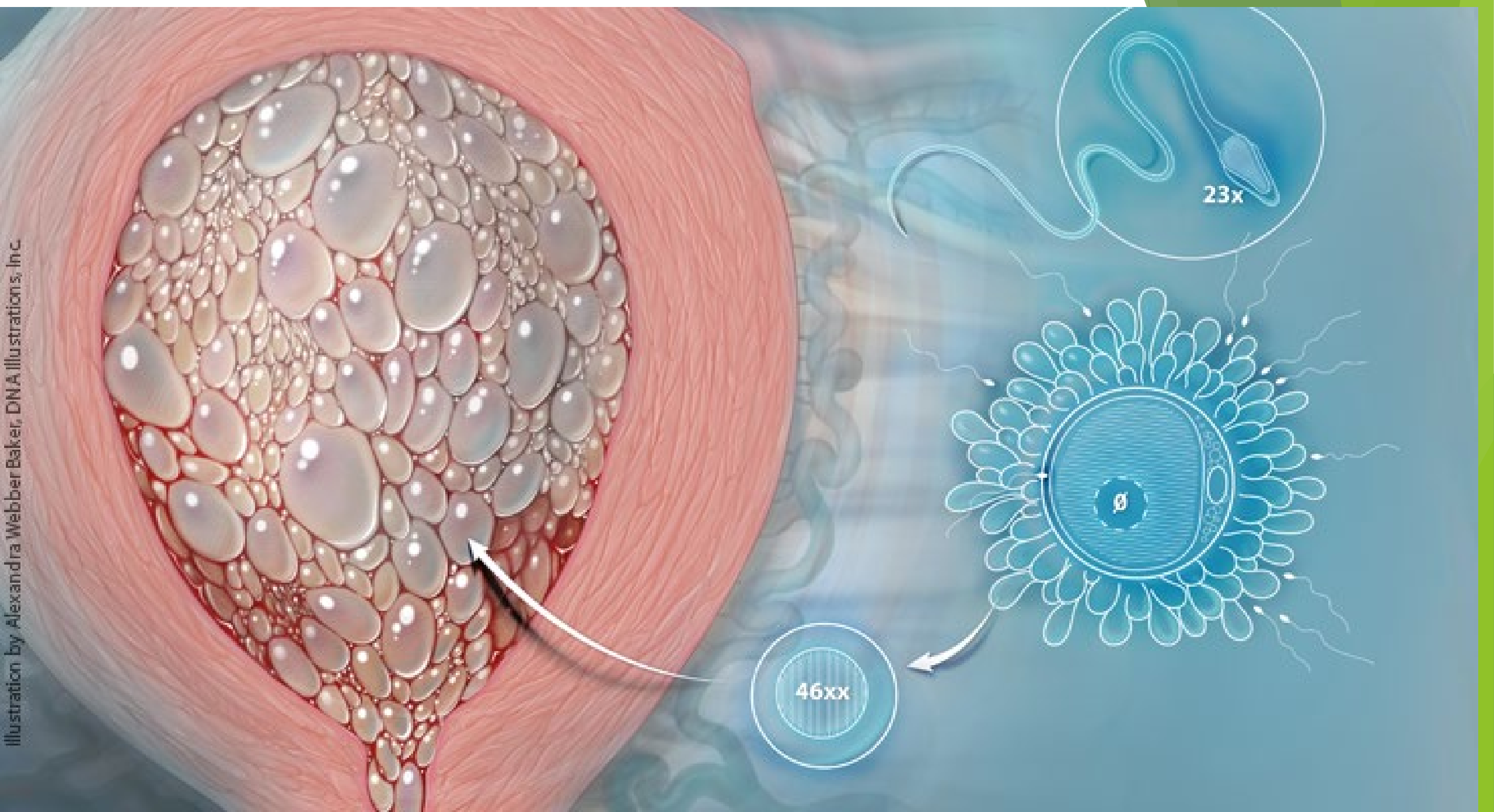
Complete mole

- ▶ Consists of diffuse hydropic villi with trophoblastic hyperplasia .This is diploid, derived from sperm duplicating its own chromosome following fertilization of an 'empty' ovum. This is mostly 46XX with no evidence of fetal tissue .

Products of conception – Complex hydatidiform mole

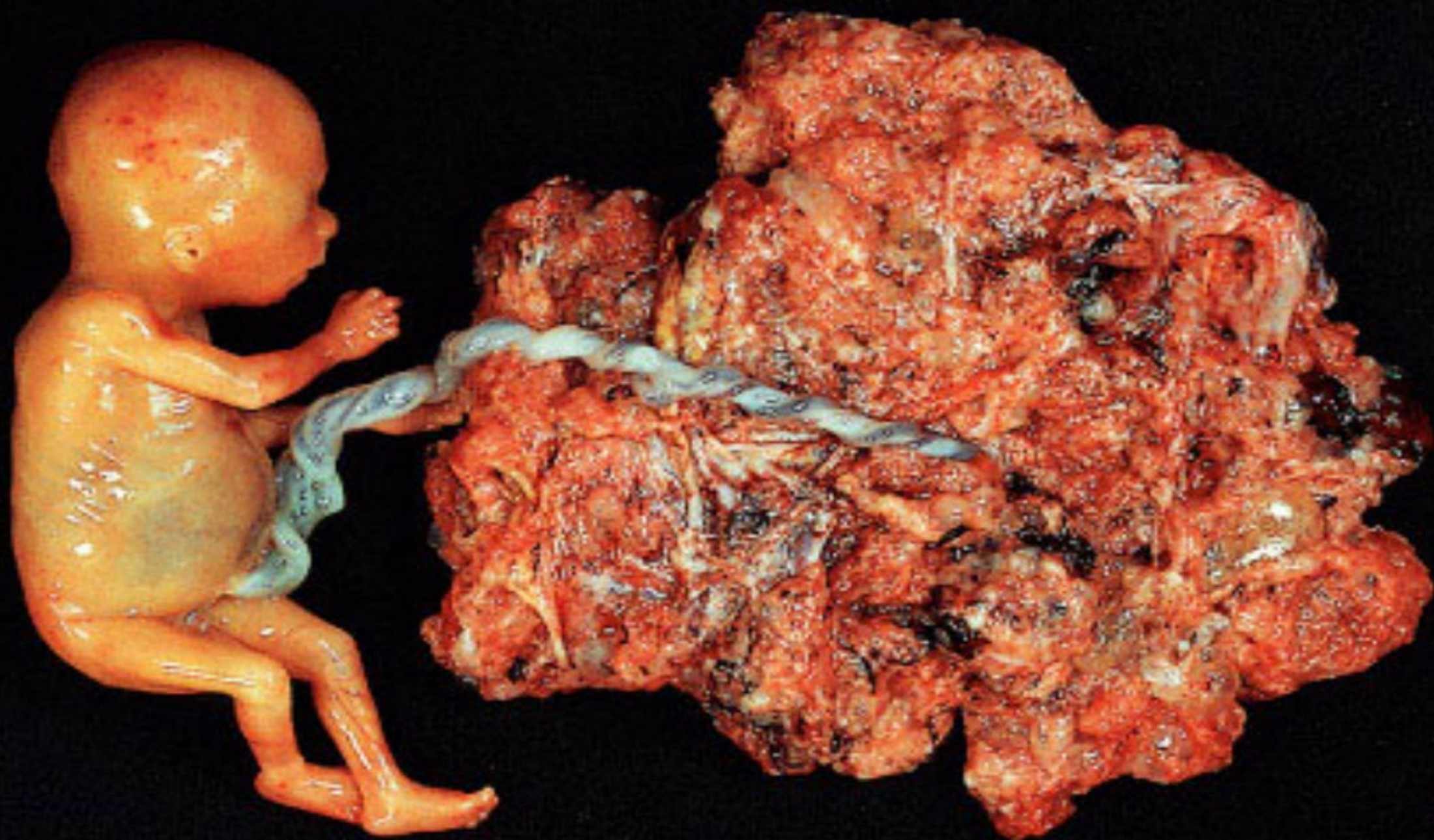
Profuse proliferation of grape-like, fluid-filled vesicles representing expanded chorionic villi

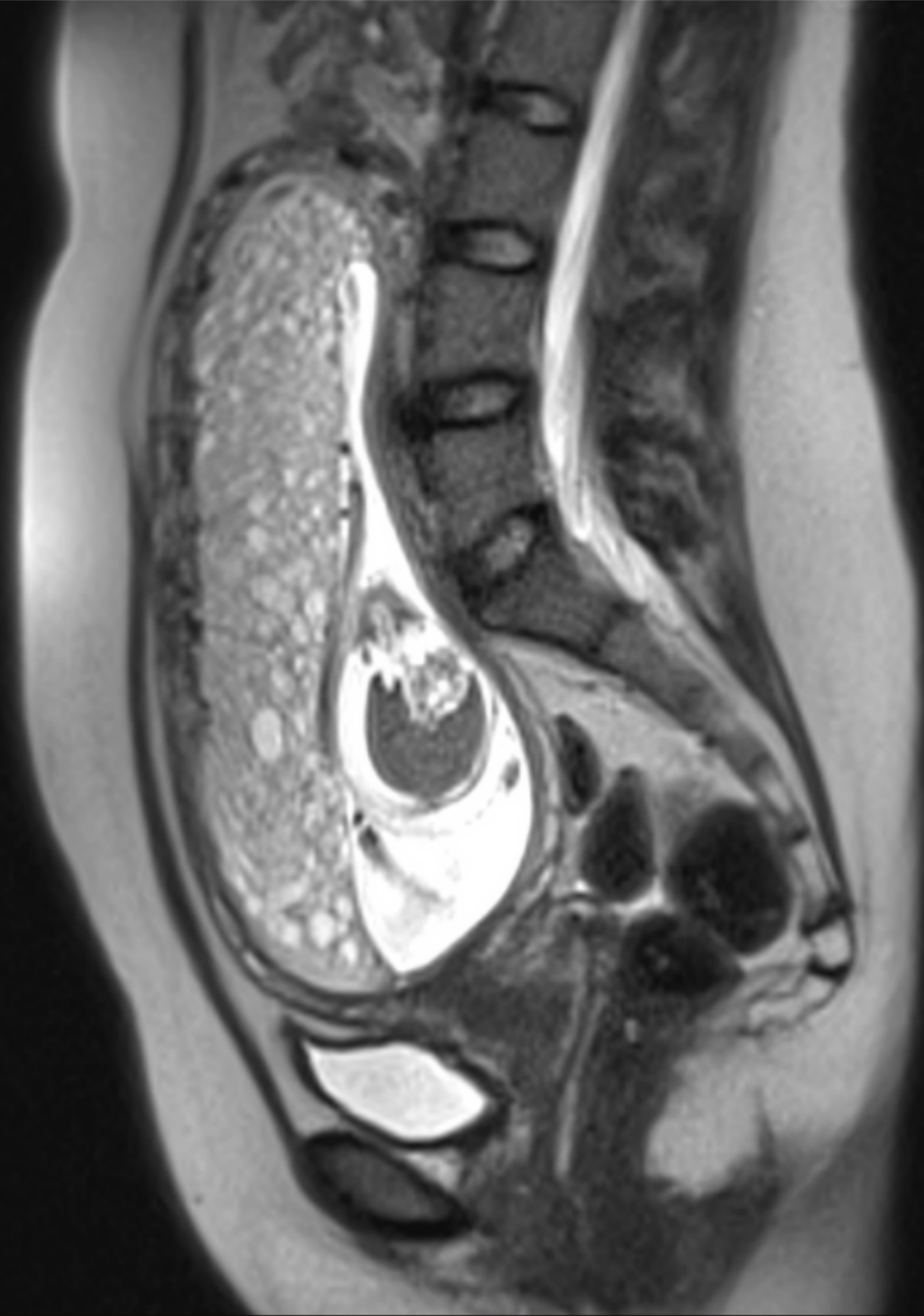
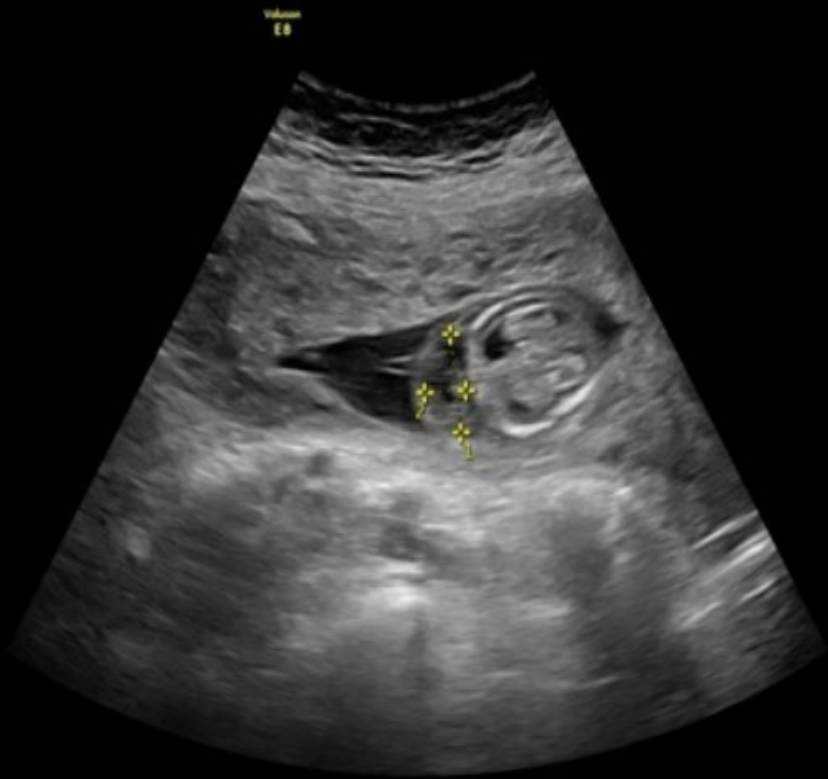



Partial mole

- ▶ Consists of hydropic and normal villi (focal hydropic villi).
- ▶ This is triploid (69XXX, XXY, XYY) with one maternal and two paternal haploid sets. Most cases occur following two sperms fertilizing an ovum, and a fetus may be present





Comparison between complete and partial mole

Hydatidiform moles are categorized into two types, which differ in their genetic makeup, pathology, and malignant potential:

Feature	Complete Hydatidiform Mole (CHM)	Partial Hydatidiform Mole (PHM)
Genetic Makeup	Diploid (<u>46,XX</u> or 46,XY), entirely Paternal origin (androgenetic). Results from an empty ovum fertilized by one sperm that duplicates its chromosomes, or by two sperm.	Triploid (<u>69,XXX</u> , 69,XXY, or 69,XYY), with Two Paternal and One Maternal set of chromosomes. Results from a normal ovum fertilized by two sperm.
Fetus/Embryo	Absent or only minimal embryonic tissue.	Usually Present but non-viable and growth-restricted.
Placental Villi	Diffuse, marked hydropic swelling ("bunch of grapes" or "snowstorm" appearance on ultrasound), and diffuse trophoblast proliferation.	Focal hydropic swelling and focal trophoblast proliferation.
Malignant Risk	Higher (15-20% risk of progression to Gestational Trophoblastic Neoplasia (GTN)).	Lower (1-5% risk of progression to GTN).
hCG Levels	<u>Typically</u> Very High (often >100,000 <u>mIU/mL</u>).	Usually Lower than CHM, often resembling spontaneous abortion.

Risk factors for hydatidiform mole :

- ▶ • Age: extremes of reproductive life (>40yrs and <15yrs of age).
- ▶ • Ethnicity: higher in east Asia, particularly Korea and Japan .
- ▶ • Previous molar pregnancy: x10 higher risk of developing future molar pregnancy.
- ▶ • Nutritional and socioeconomic factors.

Diagnosis

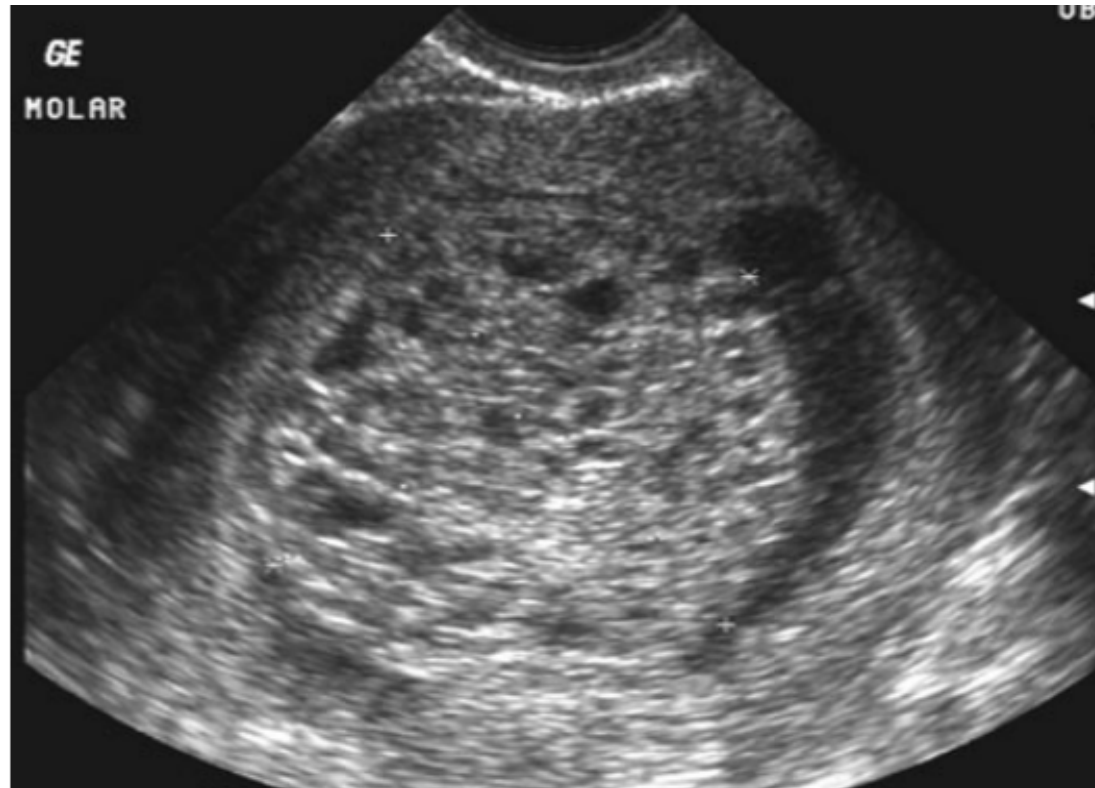
▶ *Symptoms and signs :*

- Irregular first-trimester vaginal bleeding (>90%).
- Uterus large for dates .
- Pain from large theca lutein cysts (20%) resulting from ovarian hyperstimulation by high hCG levels .
- Vaginal passage of vesicles containing products of conception (10%).

- Exaggerated pregnancy symptoms :
 - hyperemesis (10%)
 - hyperthyroidism (5%).
 - early pre-eclampsia (5%).
- *Serum hCG* is excessively high with complete moles, but levels may be within the normal range for partial moles .Extremely high levels (>100,000 mIU/mL) are highly suggestive of a CHM.

► *USS findings:*

- 1. Complete mole ' :Snowstorm' appearance of mixed echogenicity, representing hydropic villi and intrauterine hemorrhage, Large theca lutein cysts .
- 2. Partial mole :Fetus may be viable, with signs of early growth restriction or structural abnormalities.



▶ **Definitive Diagnosis: Histopathological examination** of the evacuated tissue is required to confirm the diagnosis and classify the mole (complete vs. partial)

► Management

- *Complete mole*: surgical evacuation(suction curettage) is advisable and should be performed by an experienced surgeon as risks of uterine perforation and hemorrhage are significant.
- Oxytocin may be required to reduce the risk of hemorrhage, but its use is associated with a theoretical risk of tissue dissemination leading to metastatic disease to the lungs or brain and should be avoided until the uterus is evacuated if possible .

- ▶ *Partial mole*: surgical evacuation is preferable, unless the size of fetal parts necessitates medical evacuation .

► **Post-Evacuation Surveillance (follow up)**

- All women with a histologically confirmed HM must be registered with a specialized **Gestational Trophoblastic Disease (GTD) Center** for follow-up and central monitoring of HCG levels.
- **β -HCG Monitoring:** Serial β -HCG levels are monitored to detect the development of post-molar GTN.

- **Complete Mole (CHM):**

- If HCG returns to normal within 56 days of evacuation, monitoring continues for **6 months** from the date of evacuation.
- If HCG takes longer than 56 days to normalize, monitoring continues for **6 months** from the date of the first normal HCG level.

- **Partial Mole (PHM):**

- Follow-up is concluded once the HCG has returned to normal on **two consecutive samples, at least 4 weeks apart.**

- **Contraception:** Contraception is strictly advised throughout the entire monitoring period because a new pregnancy would produce HCG, obscuring the surveillance of the molar tissue regression.

Diagnosis of Post-Molar Gestational Trophoblastic Neoplasia (GTN)

(Indications of chemotherapy)

- ▶ GTN is diagnosed if the β -hCG follow-up criteria are met:
- ▶ **Plateau:** Four values of β -hCG over a ≥ 3 -week period, with a change of $\leq 10\%$. (e.g., days 1, 7, 14, and 21).
- ▶ **Rise:** A $\geq 10\%$ increase in β -hCG over three values, sustained over a ≥ 2 -week period. (e.g., days 1, 7, and 14).
- ▶ **Persistence:** Persistent detectable β -hCG for ≥ 6 months after evacuation.
- ▶ **Histological Diagnosis:** Any confirmed histology of choriocarcinoma.

► *Indications of hysterectomy in the management of GTD:*

- 1.Choice (older patient ,localized disease ,family complete).
- 2.Excessive uterine bleeding (before or during treatment).
- 3.Chemoresistant (localized) uterine tumour.
- 4.Placental site trophoblastic tumour.

▶ *Prognosis*

- ▶ With effective registration and treatment programmed, cure rate is high (98-100)
- ▶ Women should be advised not to conceive until HCG level has been normal for 6 months .
- ▶ HCG level should be checked 6 and 10 weeks after each subsequent pregnancy .

choriocarcinoma

- ▶ This is a highly malignant tumor consisting of syncytio- and cytotrophoblast with myometrial invasion. Local spread and vascular metastases to the lung are common, also metastases to the pelvic organs , liver and brain. 50% of cases are preceded by hydatidiform mole.

Placental site trophoblastic tumor

- ▶ These tumors have slow growth rate & can present many years after term delivery ,non-molar miscarriage or complete mole.
- ▶ The usual presentation is with local disease leading to vaginal bleeding or amenorrhea , but they may also metastasize particularly to the lung .
- ▶ Surgery alone is the treatment of choice for localized disease ,chemotherapy is needed for metastatic tumor.

Invasive mole

- ▶ Excessive trophoblastic over growth & extensive penetration by the trophoblastic cells including the villi .
- ▶ Invasive mole penetrate in to the myometrium & sometimes the peritoneum , parametrium & vaginal vault but lack the tendency to widespread metastasis typical of choriocarcinoma

A scenic view of a traditional village with thatched-roof houses and a stone path. The houses are built with wood and have steeply pitched roofs made of dried palm leaves or similar natural materials. The village is surrounded by lush greenery, including banana trees and other tropical plants. A stone path leads through the village, and a wooden fence made of branches is visible in the foreground. The overall atmosphere is peaceful and rural.

THANK YOU